



# THE ANNALS OF THORACIC SURGERY



## **A Multidisciplinary Approach to the Minimally Invasive Pulmonary Vein Isolation for Treatment of Atrial Fibrillation**

Sotiris C. Stamou, Kamal R. Khabbaz, Feroze Mahmood, Peter Zimethbaum and Robert  
C. Hagberg

*Ann Thorac Surg* 2010;89:648-650  
DOI: 10.1016/j.athoracsur.2009.04.085

The online version of this article, along with updated information and services, is  
located on the World Wide Web at:

<http://ats.ctsnetjournals.org/cgi/content/full/89/2/648>

*The Annals of Thoracic Surgery* is the official journal of The Society of Thoracic Surgeons and the Southern Thoracic Surgical Association. Copyright © 2010 by The Society of Thoracic Surgeons. Print ISSN: 0003-4975; eISSN: 1552-6259.

# A Multidisciplinary Approach to the Minimally Invasive Pulmonary Vein Isolation for Treatment of Atrial Fibrillation

Sotiris C. Stamou, MD, PhD, Kamal R. Khabbaz, MD, Feroze Mahmood, MD, Peter Zimetbaum, MD, and Robert C. Hagberg, MD

Division of Cardiothoracic Surgery, Department of Anesthesia, and the Division of Cardiology, Beth Israel Deaconess Medical Center, Harvard Medical School, Boston, Massachusetts

Bilateral pulmonary vein isolation along with amputation of the left atrial appendage has become a well-recognized technique for the management of atrial fibrillation. We describe our multidisciplinary approach to minimally invasive bilateral pulmonary vein isolation, left atrial appendage resection, and ablation of autonomic ganglia.

(Ann Thorac Surg 2010;89:648–50)

© 2010 by The Society of Thoracic Surgeons

**M**inimally invasive surgical pulmonary vein isolation (PVI) was first introduced several years ago and has now become an accepted modality to treat patients with atrial fibrillation (AF) [1]. Many different energy sources have been used to accomplish epicardial lesions; however, bipolar radiofrequency (RF) ablation may be more reliable in creating transmural lesions [2]. We describe our multidisciplinary surgical approach to PVI, electrophysiologic testing, autonomic ganglia mapping, and ablation, as well as complete resection of the left atrial appendage (LAA).

## Technique

After general endotracheal double lumen tube anesthesia is achieved, the patient is placed in the left lateral decubitus position and the right chest is prepped and draped. A 4-cm incision is used to gain access to the fourth intercostal space spanning the axillary line. Then a reusable rib retractor is inserted. The pericardium is opened 3 cm anterior to the phrenic nerve and is extended inferiorly and superiorly. Sharp dissection between the inferior vena cava and the right inferior pulmonary vein provides access to the oblique sinus. A dissector (Lumitip Dissector [Atricure, Cincinnati, OH] or Cardioblade Navigator Tissue Dissector [Medtronic Inc, Minneapolis, MN]) is then inserted through a 1.5-cm incision in the anterior axillary line in the seventh interspace, and it is used to bluntly dissect around the right-sided pulmonary veins sweeping inferiorly to su-

periorly. A silastic catheter is left in place of the dissector, which later facilitates the placement of a bipolar RF clamp. We then test for entrance and exit conduction prior to any ablative procedure. Signals are acquired with a handheld multifunctional electro-surgical device (Isolator Multifunctional Pen [Atricure] or Cardioblade MAPS Device [Medtronic Inc]) connected to a monitoring-pacing system (Prucka CardioLab EP System [GE Medical Systems, New York, NY]). We then test for reactive autonomic ganglia in different locations around the pulmonary veins using the same devices by pacing at high frequency (800/minute, 12 to 16 mA, pulse duration 10 ms). A positive response is defined as a > 50% prolongation of the RR interval. Radiofrequency energy (Isolator Multifunctional Pen and ASU/ASB Generator [Atricure] or Cardioblade MAPS and 680 Generator [Medtronic Inc]) is then used to ablate positive ganglia. These locations are then re-tested to confirm successful ablation. Waterston's groove is then developed using electrocautery. A bipolar RF clamp (Isolator Synergy Clamp [Atricure] or Cardioblade Gemini Surgical Ablation System [Medtronic]) is then advanced into position using the previously placed silastic catheter, and it is used to electrically isolate the right-sided pulmonary veins. The clamp is applied to a cuff of atrial tissue, which is approximately 1 to 2 cm away from the ostia of both right-sided pulmonary veins. The device is applied and bipolar RF ablation performed for a total of three times with the clamp in a different orientation (ie, neutral, toe slightly in, heel slightly in) each time. Fifteen minutes after the last ablation, entrance and exit block are confirmed. If needed, additional ablations are performed until bidirectional block is obtained. A soft pleural drain is placed through the dissector insertion site and the incision is closed in layers.

The right lung is re-inflated and the patient is placed in the right lateral decubitus position. The left chest is prepared and a 4-cm incision spanning the axillary line is made to enter the third intercostal space. The pericardium is opened posterior to the phrenic nerve. A path around the left pulmonary veins is then created using the

Accepted for publication April 21, 2009.

Address correspondence to Dr Hagberg, 110 Francis St, Suite 2A, Boston, MA 02215; e-mail: rhagberg@bidmc.harvard.edu.

Dr Hagberg discloses that he has a financial relationship with Medtronic Inc.

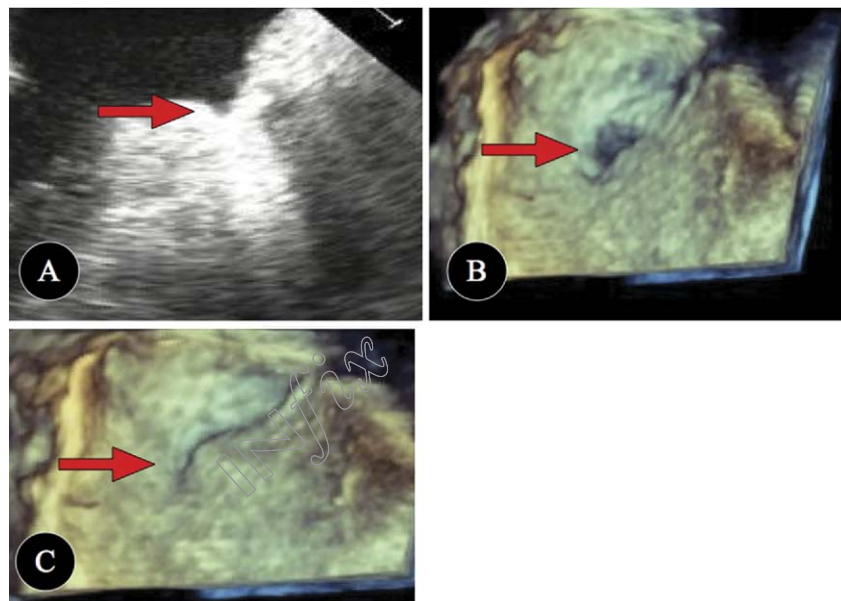


Fig 1. Demonstrates residual stump after first resection of left atrial appendage (LAA) in two-dimensional (panel A) and three-dimensional (3-D) transesophageal echocardiographic (TEE) (panel B). Panel C shows 3-D TEE image confirming complete obliteration of LAA after placing additional sutures.

same technique as previously described for the right side. The dissector insertion site should be slightly more lateral than on the right side so that the same incision can be used to introduce the endoscopic gastrointestinal anastomosis stapler for LAA resection. The stapler should have a direct path to the base of the LAA, such that there is no torque applied to the heart when resecting the LAA. The ligament of Marshall is divided with electrocautery. Electrophysiologic testing and ablations are carried out using the same technique as described for the right side. The LAA is then resected using an endoscopic gastrointestinal anastomosis stapler with the 4.8 mm staple load (Powered Multifire Endoscopic GIA 60 [Covidien, Norwalk, CT]). This is done under real time three-dimensional (3-D) transesophageal echocardiographic (TEE) guidance performed by our anesthesia team to make sure that there is no residual stump. If there is any residual stump left over, strategic placement of pledgeted 4.0 Prolene stitches (Ethicon Inc, Somerville, NJ) is done under 3-D TEE guidance to completely obliterate the LAA (Fig 1).

### Comment

The described technique allows for safe and reliable electrical isolation of pulmonary veins and resection of LAA, while avoiding the morbidity of median sternotomy and cardiopulmonary bypass. It also allows for sophisticated electrophysiologic testing, which we believe is essential in assessing the adequacy of PVI as well as the detection and ablation of active ganglia. This technique uses a cosmetically acceptable 4-cm incision allowing for direct visualization of the surgical site with minimal rib spreading. We believe that direct visualization is especially important when dealing with the LAA, as additional sutures needed for either hemostasis or to obliterate any residual LAA stump can be done quickly and

easily through a mini-thoracotomy approach and may be technically quite challenging with a totally thoracoscopic approach. Between 2006 and 2008, the procedure was performed in 20 patients. Twelve patients have completed 1-year follow-up (7 with paroxysmal AF and 5 with persistent, longstanding AF), whereas the rest of the procedures were performed more recently on patients. Our success rate is 100% for those with paroxysmal AF and only 40% for those with persistent or longstanding persistent AF (3 of 5 failures). There have been no deaths, no conversions, no major bleeding events or procedure abortions, and the most frequent complication has been latent pericarditis (3 of 20 [15%]). Our postoperative protocol includes continuation of the antiarrhythmic that was already in use, but we do not start any new drugs prophylactically. Warfarin is started on postoperative day 1 and continued until the patient is in sinus rhythm continuously for 6 months and off all anti-arrhythmics for at least 3 months.

A multidisciplinary approach that includes an electrophysiologist and an anesthesiologist experienced with 3-D TEE can not be overemphasized, as each is essential for quality control. Sophisticated intraoperative electrophysiologic testing is essential for this technique, because we have frequently had to perform more than the initial three ablations to achieve complete electrical isolation of the pulmonary veins. We have also found that developing Waterston's groove not only obliterates any ganglia that may be in that location, but also, allows for direct application of the bipolar clamp onto left atrial muscle rather than fat, which may allow for a more successful ablation. Atrial tachyarrhythmias after ablation procedures have been reported and are most commonly caused by incomplete or nontransmural ablation lines [2]. In addition, the most common cause of failure with catheter-based PVI is pulmonary vein reconnection [2]. Bipolar RF

ablation reduces these risks by more reliably producing lesions that are transmural [1]. A 3-D TEE is preferred to two-dimensional TEE, because what appeared to be adequate LAA obliteration on two-dimensional TEE was not always adequate on 3-D TEE. Similarly, a previous study demonstrated that after surgical “closure” of the LAA, a substantial proportion (60%) of patients had findings, even on two-dimensional TEE suggestive of incomplete or failed closure that may keep patients at risk for future cardioembolic phenomena [3]. Follow-up will determine the long-term efficacy of this technique in terms of freedom from AF, as well as the potential for stroke risk reduction. We believe that PVI alone is appropriate for patients with paroxysmal AF, but more exten-

sive lesions may be necessary for patients with persistent or longstanding persistent AF.

## References

1. Wolf RK, Schneeberger EW, Osterday R, et al. Video-assisted bilateral pulmonary vein isolation and left atrial appendage exclusion for atrial fibrillation. *J Thorac Cardiovasc Surg* 2005;130:797–802.
2. Kobza R, Hindricks G, Tanner H, et al. Late recurrent arrhythmias after ablation of atrial fibrillation: incidence, mechanisms, and treatment. *Heart Rhythm* 2004;1:676–83.
3. Kandarian AS, Gillinov AM, Pettersson GB, Blackstone E, Klein AL. Success of surgical left atrial appendage closure: assessment by transesophageal echocardiography. *J Am Coll Cardiol* 2008;52:924–9.

## A Multidisciplinary Approach to the Minimally Invasive Pulmonary Vein Isolation for Treatment of Atrial Fibrillation

Sotiris C. Stamou, Kamal R. Khabbaz, Feroze Mahmood, Peter Zimetbaum and Robert C. Hagberg

*Ann Thorac Surg* 2010;89:648-650  
DOI: 10.1016/j.athoracsur.2009.04.085

### Updated Information & Services

including high-resolution figures, can be found at:  
<http://ats.ctsnetjournals.org/cgi/content/full/89/2/648>

### References

This article cites 3 articles, 2 of which you can access for free at:  
<http://ats.ctsnetjournals.org/cgi/content/full/89/2/648#BIBL>

### Subspecialty Collections

This article, along with others on similar topics, appears in the following collection(s):  
**Electrophysiology - arrhythmias**  
[http://ats.ctsnetjournals.org/cgi/collection/electrophysiology\\_arrhythmias](http://ats.ctsnetjournals.org/cgi/collection/electrophysiology_arrhythmias)

### Permissions & Licensing

Requests about reproducing this article in parts (figures, tables) or in its entirety should be submitted to:  
<http://www.us.elsevierhealth.com/Licensing/permissions.jsp> or  
email: [healthpermissions@elsevier.com](mailto:healthpermissions@elsevier.com).

### Reprints

For information about ordering reprints, please email:  
[reprints@elsevier.com](mailto:reprints@elsevier.com)



THE ANNALS OF  
THORACIC SURGERY

